

poechoic areas and had variable internal reflectivity, mostly medium to high (**Figure 2**).

A systemic workup was obtained, including magnetic resonance imaging of the brain and orbit, computed tomography of the chest, abdomen, and pelvis, and a bone scan. Computed tomography demonstrated multiple pulmonary nodules and prominent lymph nodes. The bone scan showed left iliac and right clavicle hot spots. Biopsy of the lung lesion confirmed metastatic prostate adenocarcinoma. His ocular lesion was presumed to be metastatic from the same primary cancer. He was treated with oral ketoconazole, 200 mg 3 times a day for 7 weeks, and 1 dose of intramuscular leuprolide acetate, 22.5 mg. At 7 weeks, visual acuity remained hand motions but the patient had a subjective improvement in vision. Ocular echography demonstrated a slight decrease in the apical dimension of the tumor. Ketoconazole was then discontinued while leuprolide acetate was maintained at a 30-mg intramuscular injection every 4 months. Five months after the initial visit, his visual acuity improved to 20/60 and retinal pigment epithelial changes appeared on the surface of the tumor. The tumor size decreased to 14.5 × 10 mm in basal dimension and a maximum apical height of 4 mm. Ten months later, the patient's visual acuity declined to counting fingers due to macular hemorrhages and choroidal atrophy. The tumor continued to decrease in size over several years. At the 5-year follow-up, the tumor has indistinct basal dimensions and a maximum apical height of 1.6 mm on echography.

**Comment.** In recent years, 2 cases of choroidal metastasis from prostate cancer have been successfully treated with hormonal therapy without radiation.<sup>5,6</sup> One patient received bicalutamide in combination with a luteinizing hormone–releasing hormone agonist, and another received bicalutamide in combination with triptorelin pamoate. The follow-up periods for these patients were 14 months and 2 years, respectively.

Our case was successfully treated with a single intramuscular injection of leuprolide every 4 months without any radiation or combination therapy. Leuprolide administration causes an initial increase in the gonadotropin level, which may last several weeks. The initial short course of ketoconazole treatment in our case was to counteract this effect. Ketoconazole reduces androgen production and also acts as an androgen receptor agonist. Even though the tumor involved the macula, the initial vision recovery was remarkable. Unfortunately, the vision was compromised by retinal hemorrhages and choroidal atrophy. Several options were offered to the patient, but he opted to not have further intervention. Subsequently, a chorioretinal macular scar developed.

To our knowledge, this is the first case of choroidal metastasis from prostate cancer successfully treated by single-agent androgen deprivation therapy and 5-year follow-up. We recommend considering leuprolide monotherapy for management of similar cases, reserving radiotherapy for unresponsive tumors.

Hossein Ameri, MD, FRCSEd, MRCOphth  
John C. Araujo, MD, PhD  
Dan S. Gombos, MD

**Author Affiliations:** Department of Ophthalmology and Visual Sciences, University of Texas Medical Branch, Galveston (Drs Ameri and Gombos), and Department of Genitourinary Medical Oncology, Division of Cancer Medicine (Dr Araujo) and Section of Ophthalmology, Department of Head and Neck Surgery, Division of Surgery (Dr Gombos), The University of Texas MD Anderson Cancer Center, Houston.

**Correspondence:** Dr Gombos, Section of Ophthalmology, Department of Head and Neck Surgery, The University of Texas MD Anderson Cancer Center, 1515 Holcombe Blvd, Unit 1445, Houston, TX 77030 (dgombos@mdanderson.org).

**Financial Disclosure:** None reported.

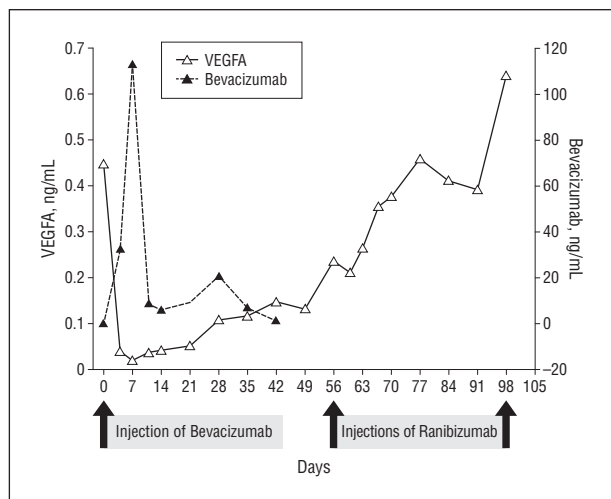
1. Garcia M, Jemal A, Ward EM, et al. *Global Cancer Facts and Figures 2007*. Atlanta, GA: American Cancer Society; 2007:1-46.
2. Kim HS, Freedland SJ. Androgen deprivation therapy in prostate cancer: anticipated side-effects and their management. *Curr Opin Support Palliat Care*. 2010;4(3):147-152.
3. Shields CL, Shields JA, Gross NE, Schwartz GP, Lally SE. Survey of 520 eyes with uveal metastases. *Ophthalmology*. 1997;104(8):1265-1276.
4. De Potter P, Shields CL, Shields JA, Tardio DJ. Uveal metastasis from prostate carcinoma. *Cancer*. 1993;71(9):2791-2796.
5. Barbón JJ, González-Tuero J, Gay LL, Pérez-García FJ, Sampedro A. Regression of a choroidal metastasis from prostate adenocarcinoma after hormonal therapy [in Spanish]. *Arch Soc Esp Ophthalmol*. 2007;82(11):715-717.
6. Primavera V, Querques G, Guigui B, et al. Choroidal metastasis from clinically regressed prostate adenocarcinoma: imaging of a rare case [in French]. *J Fr Ophthalmol*. 2008;31(9):877-882.

### Reduction of Vascular Endothelial Growth Factor A in Human Breast Milk After Intravitreal Injection of Bevacizumab but Not Ranibizumab

**A**nti-vascular endothelial growth factor (VEGF) drugs such as bevacizumab (Avastin) and ranibizumab (Lucentis) are increasingly used in patients with choroidal neovascularization owing to causes other than wet age-related macular degeneration, such as myopia and chorioretinitis, and in patients with macular edema due to retinal vein occlusion or diabetes mellitus.<sup>1</sup> These conditions often affect younger patients and include women of child-bearing potential. There are only very limited data about the use of anti-VEGF agents in pregnant or nursing women.

In this case study, serum and breast milk of a 32-year-old patient were analyzed for the concentrations of VEGFA and bevacizumab before and after intravitreal injection of bevacizumab and ranibizumab.

**Methods.** A 32-year-old woman, who was breastfeeding her 12-week-old son, was diagnosed as having scar-associated choroidal neovascularization in her left eye. Treatment with intravitreal bevacizumab was recommended. With preliminary data of VEGFA concentrations after the first injection of bevacizumab available, the treatment was changed to ranibizumab. After 3 injections, no signs of active choroidal neovascularization were detected. Informed consent was obtained before any study-related procedure was performed. The institutional review board waived approval. The study was con-



**Figure 1.** Concentrations of vascular endothelial growth factor A (VEGFA) and bevacizumab in the serum.

ducted following the principles outlined in the Declaration of Helsinki.

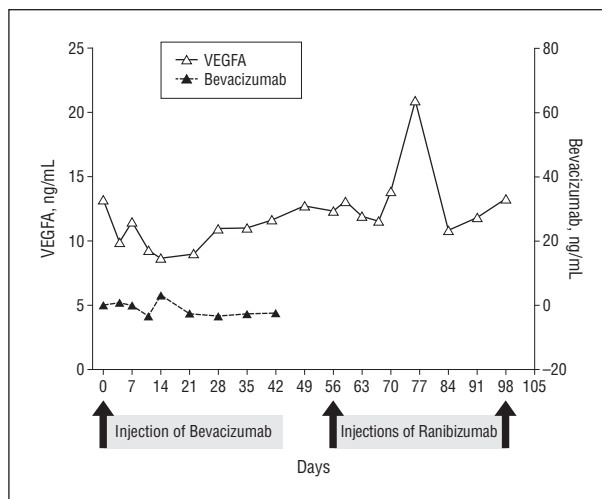
The samples were analyzed by enzyme-linked immunosorbent assay using a commercially available kit for detection of VEGFA (R&D Systems, Inc) and for bevacizumab using a protocol similar to one described by Ziemssen et al.<sup>2</sup>

**Results.** The VEGFA and bevacizumab levels in serum and breast milk are shown in **Figure 1** and **Figure 2**, respectively. After 1 injection, the serum VEGFA level decreased rapidly within 1 week to a nondetectable level. During this time, bevacizumab was detected in the serum with a peak concentration after 1 week. After 3 weeks, a steady increase of the VEGFA serum level was measured until week 8. At this point, the clinical criteria for reinjection were met and ranibizumab was injected. Four days after ranibizumab injection, the VEGFA level decreased only by 10% and began to increase again after only 3 more days.

After intravitreal treatment with bevacizumab, the VEGFA level in breast milk slowly decreased, from 13.3 ng/mL to 8.6 ng/mL after 2 weeks, marking a decrease of 35%. In the following weeks, the VEGFA level recovered slowly. Following the intravitreal injection of ranibizumab, the level of VEGFA in breast milk remained stable without significant alterations except for 1 outlier. No free bevacizumab was detected in breast milk at any time.

**Comment.** To our knowledge, this is the first description of a significant effect of treatment with intravitreal bevacizumab, but not ranibizumab, on VEGFA levels in serum and breast milk.

This distinction could be explained by a difference in the molecular structure of the proteins: whereas bevacizumab consists of a humanized IgG antibody with a fragment crystallizable (Fc) region, ranibizumab consists of only the fragment antigen-binding (Fab) region. It has been shown that Fc-containing antibodies can be transferred across the blood-retina barrier and the placenta via the Fc receptor of the neonate (FcRn).<sup>3,4</sup> Both VEGFA



**Figure 2.** Concentrations of vascular endothelial growth factor A (VEGFA) and bevacizumab in breast milk.

and its receptors are important in the rodent mammary gland during pregnancy and lactation,<sup>5</sup> and VEGFA receptors are expressed in the human newborn intestine, although their function has not yet been explained.<sup>6</sup>

Based on our data, the possibility of adverse events in the mother or the infant by reduction of the VEGFA levels in the serum or breast milk after intravitreal bevacizumab cannot be excluded. Consequently, in our opinion, if anti-VEGF treatment is required in nursing women, ranibizumab should be preferred to bevacizumab because of a lower effect on VEGFA levels in the serum and breast milk.

Christoph Ehlken, MD  
Gottfried Martin, MD  
Andreas Stahl, MD  
Hansjürgen Thomas Agostini, MD

**Author Affiliations:** Department of Ophthalmology, University Eye Hospital Freiburg, Freiburg, Germany.

**Correspondence:** Dr Ehlken, Department of Ophthalmology, University Eye Hospital Freiburg, Killianstrasse 5, 79106 Freiburg, Germany (christoph.ehlken@uniklinik-freiburg.de).

**Financial Disclosure:** None reported.

1. Chang LK, Spaide RF, Brue C, Freund KB, Klancnik JM Jr, Slakter JS. Bevacizumab treatment for subfoveal choroidal neovascularization from causes other than age-related macular degeneration. *Arch Ophthalmol.* 2008;126(7):941-945.
2. Ziemssen F, Zhu Q, Peters S, et al; Tuebingen Bevacizumab Study Group. Intensified monitoring of circadian blood pressure and heart rate before and after intravitreal injection of bevacizumab: preliminary findings of a pilot study. *Int Ophthalmol.* 2009;29(4):213-224.
3. Kim H, Robinson SB, Csaky KG. FcRn receptor-mediated pharmacokinetics of therapeutic IgG in the eye. *Mol Vis.* 2009;15:2803-2812.
4. Chaparro M, Gisbert JP. Transplacental transfer of immunosuppressants and biologics used for the treatment of inflammatory bowel disease. *Curr Pharm Biotechnol.* 2011;12(5):765-773.
5. Pepper MS, Baetens D, Mandriota SJ, et al. Regulation of VEGF and VEGF receptor expression in the rodent mammary gland during pregnancy, lactation, and involution. *Dev Dyn.* 2000;218(3):507-524.
6. Vuorela P, Andersson S, Carpén O, Ylikorkala O, Halmesmaki E. Unbound vascular endothelial growth factor and its receptors in breast, human milk, and newborn intestine. *Am J Clin Nutr.* 2000;72(5):1196-1201.